

Turner Syndrome: Update the Paradigm of Diagnosis, Clinical Care and Consequences of Y cell lines

S IQBAL

ABSTRACT

Turner's syndrome (TS) is a common chromosomal aneuploidy, present in humans with an incidence rate of 1:2500 of the new-born infants with phenotypic females. It is due to sex chromosomal monosomy with 45X karyotype, characterized by short stature, primary amenorrhea and specific somatic abnormalities, present in more than 60% of the cases. Rest of the cases presented with chromosomal mosaicism in which 45X cell line is accompanied by structurally abnormal X/Y chromosomes. The presence of Y chromosome material in TS patients has ovarian dysgenesis, which increases the risk of developing gonadoblastoma and other germ cell tumours. The Y derived sequences produce virilization characteristics in TS females during puberty. Even though gonadoblastoma is a benign tumour, it undergoes transformation into malignant dysgerminoma in 60% of the patients. So mosaicism of both X/Y chromosomes is common in TS and detection of Y-specific sequences is necessary to prevent development of gonadal tumours. Prophylactic gonadectomy should be recommended in Turner's patients with Y chromosomal mosaicism. TS

patients should be investigated with polymerase chain reaction (PCR) which is highly sensitive, cost effective and easy to perform in addition to routine cytogenetic analysis to detect Y chromosomal sequences. Fluorescence In Situ Hybridization (FISH) using specific chromosomal probes is also used to confirm the cytogenetic results. A revised paradigm using a standard multi-disciplinary approach is essential in the management of TS females based on the knowledge, awareness and adverse outcome of various organ systems from birth to adulthood. This modified approach gives an optimized medical care for all Turner's syndrome patients to reduce the morbidity and mortality, and make them happy, healthy and to lead an independent life as useful and productive members of the society. A thorough Pubmed and other related search for over the past 15 years identified the available studies related to clinical features, diagnosis, management as well as the consequences of the Y-derived sequences of TS. This clinical review summarizes the inputs of various studies through 2013 and highlights recent developments.

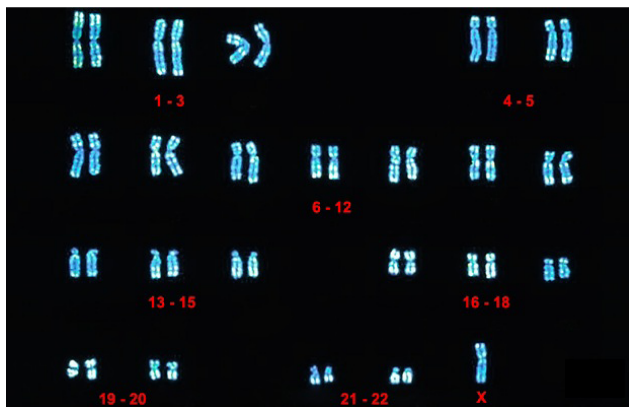
Key Words: Dysgerminoma, Gonadoblastoma, Isochromosome, Karyotype, Mosaicism, Virilization

INTRODUCTION

Turner's syndrome (TS) is a genetic disorder, affects females with short stature, primary amenorrhea and sexual infantilism. It is associated with cubitus valgus, webbed neck, low posterior hair line, low-set ears, widely spaced nipples and lymphedema of extremities [1]. TS is the most common chromosomal aneuploidy with an incidence rate of 1:2500 among new born females [2]. This is caused by a partial or complete absence of one X chromosomes (45X) in some or all cells [3] [Table/Fig-1]. This karyotype was found in 1-2% of all pregnancies, out of which 99% have spontaneous abortion. Less than 1% of 45X fetuses survive to term [4]. Approximately 60% of all TS cases has 45X karyotype, 5-10% of cases show X chromosome anomalies viz., deletions of long/short arms, isochromosomes or ring chromosomes. The

remainder of the cases shows mosaicism for 45 X with one or more additional cell lineages. About 6-9% of cases shows a normal or structurally abnormal Y chromosomes or Y derived sequences [5-7].

Most of the TS females have streak gonads which serve as a risk factor for the development of germ cell tumors. Gonadoblastoma, the benign precursor lesion later undergo transformation into malignant, invasive dysgerminoma in the presence of Y chromosomes or Y derived sequences in 60% of the patients [8,9]. The critical region for developing gonadoblastoma has been localized to a small area near centromere of the Y chromosome [10]. Early detection of Y derived sequences is of great importance in TS females, because of the high risk of (10-30%) developing gonadal tumours. Prophylactic gonadectomy should always be



[Table/Fig-1]: Karyotype of Turner's syndrome (45X)

advised in patients with TS with the presence of Y cell lines or Y mosaicism [11].

Although short stature and primary amenorrhea with absent secondary sexual characters are the primary clinical features of TS, many other systems and tissues may also be affected with greater or lesser extent leading to complexity in the diagnosis of TS. Conventional cytogenetic analysis of peripheral blood lymphocytes with G-T-G banding is widely used to analyze the abnormal sex chromosomes. But in many Turner's mosaic patients, Y chromosomes were present in a small percentage of cells; a more sensitive PCR technique may be utilized to identify the cryptic Y chromosome [8]. The more advanced molecular Fluorescence in situ hybridization (FISH) technique can be used to identify the precise percentage of Y cell lines, as large number of cells can be screened in this method [8]. The morbidities associated with the TS may have a profound effect in the quality of life and an integrated, multi-disciplinary approach is needed to tackle this illness. The present clinical review analyzes the latest developments in the diagnostic modalities, tries to update the recent advances in the management of the Turner's syndrome and the consequences of Y cell lines.

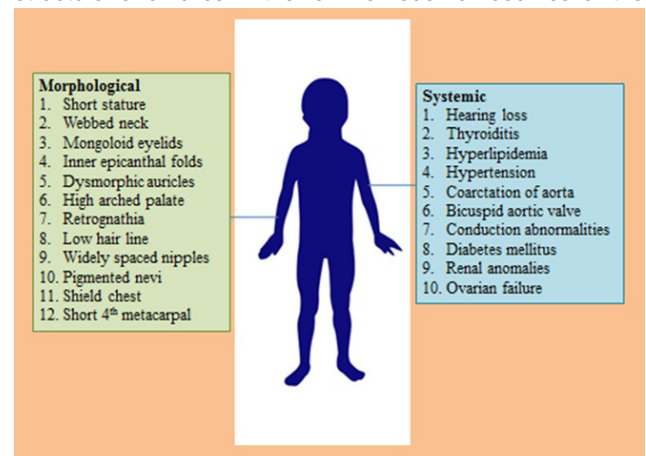
Clinical features

Growth failure and gonadal dysgenesis are the two important clinical features of TS. Growth failure begins prenatally, with poor growth, often evident within first three years of life. The adult height is on average 20 cm below the expected norms [12]. The terminal short arm of X chromosome and pseudoautosomal region contain two important genes for linear growth viz., Pseudoautosomal homeobox osteogenic gene (PHOG) and Short Stature homeobox gene (SHOX). These growth promoting genes are located at Xp22 and Yp11.3 in the pseudoautosomal regions of the sex chromosomes which are lost due to the result of translocation. The haploid insufficiency of these genes are responsible for growth failure and various other skeletal anomalies of the Turner's girls [13,14].

Women with TS have undifferentiated gonads with normal female external genitalia. Ovaries become a pair of fibrous streaks, without germ cells or ovarian follicles due to deficient hormonal stimulus. Premature ovarian failure occurs due to the death of oocytes and most of ovarian tissue degenerates before birth. The affected girls do not undergo puberty and so are unable to conceive. The uterus in these cases appears to be small, and unable to carry conception, so most of them are infertile [15]. The morphological anomalies include obliquely placed (dysmorphic) auricles, anti-mongoloid slanting of eyelids, inner epicanthal folds, high arched palate, receding jaw (retrognathism), widely spaced nipples, and short sternum. Cardiovascular anomalies in the form of coarctation of the aorta and ventricular septal defects, renal anomalies viz., horse-shoe kidneys and unilateral agenesis, bicornuate uterus and fourth and fifth metacarpal-metatarsal hypoplasia are also seen in most of the patients. Primary amenorrhea with stunted breast growth is also found due to endocrine insufficiency. The Turner's females also had the risk of suffering from high blood pressure, kidney problems, diabetes, cataracts, osteoporosis, and thyroid problems [15,16]. Most of the patients have normal intelligence quotient (IQ). Some of them have developmental delays, non-verbal learning disabilities, and behavioral problems, although these problems vary among different individuals. Autoimmune diseases like hypothyroidism, celiac disease and diabetes mellitus are also frequently found associated with Turner's patients, but the causative factor remains unexplained. But some believe that karyotype with X isochromosome is invariably found associated with autoimmune diabetes mellitus [2,15,17]. The clinical features of the TS are summarized in [Table/Fig-2].

Genetic characteristics

About 50-60% of the TS patients presents with karyotype 45X, a sex chromosomal monosomy with phenotypic females [2,18]. Remaining 30% of the patients, show X chromosome structural anomalies in the form of isochromosomes of the



[Table/Fig-2]: Clinical features of Turner's syndrome

long arm, dicentric chromosomes, deletion of the short arm or ring chromosomes. These chromosomal structural anomalies were seen in patients with homogeneous karyotype or 45X cell line mosaics. Around 5% of patients accounted for structural abnormalities of Y chromosomes, viz., isochromosomes of the long arm and dicentric chromosomes and Y cell line mosaics or overt Y derived sequences [2,7,14]. Most live born 45X infants present with more than one cell karyotype, i.e., in the form of mosaic with additional sex chromosome. This was present only in certain organs and it is essential for the fetus to survive. This was confirmed by the fact that sex chromosomes mosaicism was more frequent in live born TS infants and 99% of embryos with pure 45X karyotype abort spontaneously in utero [19,20].

The incidence of TS does not increase with maternal age unlike that of other numerical chromosomal anomalies such as trisomy 21 (Down syndrome)/trisomy 18 (Edwards syndrome) [21]. These observations are against the meiotic nondisjunction as the cause of occurrence of 45X karyotype. In analyzing the clinical features of Turner's syndrome, the pure 45X karyotype presents with only short stature with other inconsistent features, which was in contrast to other chromosomal syndromes. This can be explained by the undetected mosaicism in Turner's patients, since majority of the Turners patients were diagnosed by analyzing 5-30 metaphase spreads of peripheral lymphocytes during karyotype analysis and the second cell lines often present only in 1 to 2% of individual cells [22]. Approximately around 99% of conceptions with 45X karyotype aborts randomly during initial stages of embryonic development, only 1% of these conceptions complete full term and born with Turner's features. This is due to the result from monosomy of the genes which were common to both X and Y chromosomes. In females it is these genes that were expressed both in the active and in the inactivated X chromosomes and these genes are responsible for the expression of Turner's characteristics [19, 20, 23].

Mosaicism

The detection of mosaicism in Turner's patients depends on the type, number of tissues examined, number of cells (metaphases) analyzed, sensitivity of the techniques used and the presence of low frequency cell lines. The conventional cytogenetic techniques failed to detect low frequency cell lines mosaicism. But highly specific molecular techniques like - FISH and PCR can able to detect low frequency cell lines with possible chromosomal structural abnormalities also [17, 23, 24]. The peripheral blood lymphocytes are common tissues used in the classical cytogenetic analysis with 30 metaphases with 10% detection of mosaicism. Since all cases of TS carry mosaicism, cell lines with frequency below 10% escapes undetected in this method. So another tissue with

different embryonic origin may be used for analysis to detect mosaics e.g., oral mucosa [25]. The molecular techniques viz., FISH and PCR has become a reliable tool in identifying the Y chromosome specific hidden moaicism. Since cytogenetic analysis of single cell series does not provide the presence of mosaicism in TS patients, additional analysis of cells from different tissues (mesodermal lymphocytes and ectodermal oral epithelial cells) may provide vital clues of mosaicism [11]. FISH analysis with chromosomal probes gives accurate results of mosaics and highlights the possibility of chromosome abnormalities/presence of second sex chromosomes in other tissues [26]. Mendes et al., [27] observed that 25% of all Turner's karyotypes have mosaicism and the Y chromosome specific sequences were encountered in approximately 40% of these cases. Lopez et al., [28] advocated a combination of classical cytogenetics with molecular DNA analysis with marker chromosomes to study the Y chromosome derived sequences. Chu et al., [29] concluded that PCR was more effective than cytogenetic analysis in detecting Y hidden mosaicism and may be more effective, using multi tissue approach. So we advocate analysis of multi tissues (blood, oral mucosa and gonadal tissue) by using FISH and PCR to found significant difference in the distribution of mosaicism among different tissues in all Turner's patients.

Y chromosomal risk factors

Patients with dysgenetic gonads develop gonadal tumors due to the abnormalities in gonadal organogenesis [30]. Gonadoblastoma is the precursor lesion usually develops in the dysgenetic gonads, which later progress to invasive germ cell tumour, dysgerminoma, and also to lesser extent to embryonic carcinoma, teratoma, yolk sac tumour and choriocarcinoma [31]. Disorders in germ cell maturation lead to gonadoblastoma which is a mixed, undifferentiated germ cell tumor, associated with hyperandrogenism which may turn malignant dysgerminoma in 60% of the cases [10]. Gonadoblastoma locus on the Y chromosome (GBY) is the gene which is related to tumours arising from dysgenetic gonads and is located within a small region of short arm of the Y chromosome, close to the centromere [9]. Testis-specific protein Y-encoded (TSPY) is a candidate gene for GBY locus, is possibly related to the development of gonadoblastoma and involvement of short arm of Y chromosome [32]. POU5F1 (OCT4) gene located in 6p21.3 is expressed in pluripotent stem cells and germ cells has shown their immune reactivity detectable in both gonadoblastoma and dysgerminoma [31]. The detection of Y chromosome specific sequences in Turner's patients is necessary to prevent the development of gonadoblastoma and the presence of signs of hyperandrogenism is also taken into consideration before initiation of growth hormone (GH) therapy. This is because excessive administration of GH in TS patients with

Y chromosome fragments may lead to the development of dysgerminoma or androgen secreting tumours [33]. The Sex-determining region Y (SRY) gene has a major role in the sex determination and differentiation, acts as a signaling chain during embryonic development and also determines the gonadal microenvironment [32]. The identification of Y chromosomal materials in TS may be done under two circumstances: in the presence of virilization characteristics and/or when marker chromosome is not identified under normal cytogenetic study. PCR technique is usually employed in these cases to identify this Y chromosomal material, with 33% incidence rate of developing into gonadoblastoma [11,34]. Also the absence of virilization features does not rule out the presence of hidden Y chromosomes. So we advocate a systemic search for the hidden Y chromosome mosaicism in all TS patients for SRY gene to prevent possible gonadal malignancies.

Evaluation of Turner's patients

Patients usually present to the OPD with history of primary amenorrhea. Family history of consanguineous marriages among the parents, birth history - whether premature or full term delivery with uneventful history; physical and mental milestones during infancy and childhood all are taken into account. Associated complaints such as headache, vomiting, seizures, drug or radiation exposures and any other co-morbid illness are also to be investigated. Developmental history of other siblings in the family is also important and accounted for. Physical examination includes height, weight; any deformity/stigmata of TS, breast, axillary, pubic hair development, pelvic examination for any hypoplastic external genitalia should also be carried out. A wide systemic examination of abdomen and cardiovascular systems is to be undertaken [35].

Investigations include routine hematology, urine analysis, bone age determination, hormonal assays include FSH, LH, estrogen, prolactin and other anterior pituitary hormones including GH. Ultrasonographic scan of abdomen for hypoplastic uterus and streak ovaries should also be done. Conventional cytogenetic analysis includes chromosomal study of peripheral blood lymphocytes with G-T-G banding in over 20-40 metaphase spreads for abnormal X or Y chromosomes [10]. In many of the Turner's mosaic patients Y chromosomes may be present in a small percentage of cells. These cryptic Y chromosomes escape identification in the conventional cytogenetic analysis. The more sensitive PCR technique has been used to identify these cryptic Y chromosomes [8]. Fluorescence in situ hybridization (FISH), the molecular cytogenetic technique can be used to identify the precise percentage of Y chromosomes and its derivatives because large number of cells can be screened in this method [36].

Prenatal screening

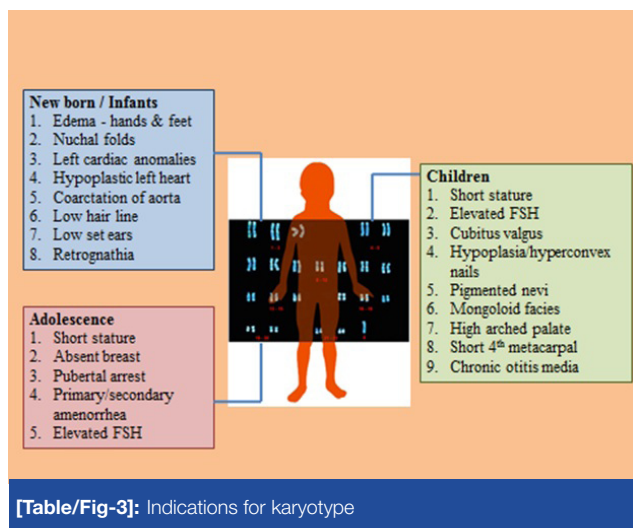
Prenatal detection of TS was noted accidentally during chorionic villous sampling and amniocentesis which were routinely performed for all cases of elderly primi to rule out any congenital anomalies. Genetic counselling with the parents was always necessary before these procedures to explain the possibility of occurrence of sex chromosome aneuploidy. Ultrasound findings (USG) include an increased nuchal translucency and cystic hygroma which likely predict TS, but this is also seen in other trisomic syndromes. Other specific USG findings include coarctation of aorta, left sided cardiac defects, brachycephaly, renal anomalies, oligo/poly hydramnios and growth retardation [4,37]. Maternal serum screening for α -fetoprotein, hCG, inhibin A and unconjugated estriol are also suggest the diagnosis of TS [38]. Prenatal karyotype confirms the diagnosis in these cases and the chromosomes were to be re-evaluated postnatally [39]. Fetuses with 45X karyotype abort spontaneously with only 1% of conceptions with either 45X or 45X/46XX and 45X/46XY mosaics complete the term, born with normal phenotype. Later these children may suffer from short stature or infertility. So prenatal counselling is advised to inform the TS parents of somatic anomalies like short stature, ovarian failure and malignant transformation of dysgenetic gonads and emphasized the current management with the sole aim that TS patients should be happy, healthy and productive members of the society [40,41].

Postnatal diagnosis

All TS patients are advised to undergo karyotype analysis postnatally. The total number of cells analyzed under metaphase spread should be sufficient to exclude the low percentage mosaicism. In addition to peripheral blood lymphocytes karyotype, a second tissue such as skin or oral mucosa may also analyzed [34]. Turner's females with virilization can be probed for Y chromosomal material. Techniques like DNA hybridization or FISH were used with a Y centromeric or short arm probe to identify the Y material. SRY gene is commonly found associated with male gonadal differentiation, recognition of SRY gene may confirm the presence of Y chromosome material in these patients [42]. The presence of Y chromosome material may cause the development of gonadoblastoma in TS patients. Previous reports accounted for a 30% risk [43], but recent researches confirm a low incidence of 7-10% risk factor [8]. So these patients are advised to go for prophylactic gonadectomy to exclude malignancy. But in abnormal situations if the patients or parents go against gonadectomy, vaginal ultrasonogram with colour Doppler sonography of gonads at regular intervals is necessary to monitor these patients with Y chromosome materials [34].

Indications for Karyotype

Turner's syndrome can be suspected in phenotypic females with growth failure and/or pubertal delay. To rule out TS, karyotype analysis should be advised in patients with the following clinical features: in the case of new-born/infant, with oedema of hands and feet, nuchal folds, left-sided cardiac anomalies, coarctation of aorta, hypoplastic left heart, low hair-line, low set ears and retrognathia; in children with short stature, decline in growth velocity (growth velocity less than 10th percentile for age), elevated levels of FSH, and any of the above mentioned signs described in infants; TS are also suspected in children with cubitus valgus, nail hypoplasia, hyperconvex uplifted nails, multiple pigmented nevi, characteristic facies, high arched palate, short fourth metacarpals, and extensive and chronic otitis media; in the case of adolescence with absent breast development by 13 years of age, pubertal arrest, primary or secondary amenorrhea, elevated FSH with short



stature. So it is advisable to analyze such patients intensively to rule out Turners syndrome [34]. The various indications for karyotype analysis are summarized in [Table/Fig-3].

Management protocols

Infancy, Childhood and Adolescence

Turner's syndrome in new-born infants was usually associated with sleeping disorders, high activity levels and with various forms of immaturity. Feeding difficulties due to high arched palate can be rectified by Rosti feeding bottles or with special teats and occasionally speech therapist and infant feeding consultant's help may be called for. A multidisciplinary approach involving a team of family physician, gynaecologist, reproductive endocrinologist, cardiologist, nephrologist, ENT specialist, dentist, fertility specialist, psychologist, dedicated nurse and a social worker may form a team to oversee the management of TS patients [44].

Congenital heart diseases (CHD) affect 30% of Turner's females. Left sided obstructive defects include bicuspid aortic valve (30%), coarctation of aorta (30%) and aortic root dilatation (5%) with risk of rupture and with associated hypertension [45]. Cardiac evaluation includes physical examination, echocardiogram with MR angiography were advised as a routine in these patients. Antibiotic prophylaxis should be instituted in patients with structural CHD. Blood pressure should be monitored annually in all cases of Turner's patients. Frequent echocardiography once in five years is advocated in all Turner's patients to rule out the aortic root dilatation. TS patients with 45X karyotype with neck webbing should be advised to have complete physical examination including blood pressure and pulse of upper and lower extremities with echocardiography to rule out coarctation of aorta. If aortic root dilatation is suspected and also with poor echocardiographic images, computed tomography or magnetic resonance imaging reveals a superior quality images indicating aortic root dilatation. Prophylaxis with beta blockers is recommended in cases with significant aortic dilatation as in the case of Marfan syndrome [2,46].

Renal anomalies were seen in 30% of TS patients in the form of rotational abnormalities and double collecting systems, which results in hypertension, urinary tract infections and hydronephrosis. Renal ultrasound with routine urine culture should be performed and appropriate therapy has to be instituted. Follow up USG and urine cultures should be repeated once in five years to such patients [2]. Primary hypothyroidism accounted for 10-30% of Turner's females. They were usually associated with anti-thyroid antibodies. Blood analysis for total T4 and TSH should be carried out to clinch diagnosis and annually afterwards as routine follow up. Some patients present with isochromosome with Xq karyotype [47].

Conductive and sensorineural hearing loss occur in 50-90% of TS females. Malformations with low set ears need to be corrected with plastic surgery. Otitis media leading to mastoiditis and cholesteatoma are very much common between 1-6 years of age, may be due to impaired growth of temporal bone. Aggressive treatment with careful follow up should be advised in these patients to prevent profound deafness. Audiological assessment should be performed regularly in these patients to identify progressive hearing loss. Speech problems are quiet common, secondary to hearing loss and ENT specialist and speech pathologist advice may be obtained in these patients [48]. Strabismus, amblyopia and ptosis are common in Turner's patients and they were evaluated annually and ophthalmologist advice needed at appropriate time. Lymphedema is common in infants, may recur in GH/estrogen therapy. Use of diuretics and tight fitting stockings can be advised. The value of surgery is still questionable. Web neck is corrected by plastic surgery; Keloid formation is a risk

factor in Turner's individuals. Hair growth in Z-plasty causes a major problem with fistula and sinus formation. Crowding and mal-occlusion of teeth results from retrognathic and small mandible. Regular orthodontic examination should be made during 8-10 years of age, in all cases of TS. Obesity is quite common in females, and it may get aggravated by stocky build, shield-like chest and short stature. Regular evaluation with appropriate counseling is needed to tackle obesity [49].

Congenital hip dislocation with associated degenerative arthritis affects both infants and older women in TS. Scoliosis affects 10% of the Turner's girls during adolescence. Regular orthopedic examination should be as part of physical examination in all TS patients [4]. Turner's females usually presented with glucose intolerance, which is aggravated by GH and oxandrolone therapy, but frank diabetes is rare among children with TS, but type II diabetes is more common in adolescence [50]. About 5% of Turner's patients are affected by coeliac disease; antibody screening should be advised in these patients with gastroenterologist's advice. Inflammatory bowel's disease - Crohn's disease is 2-3 times more common in TS, associated with isochromosome, Xq karyotype as in autoimmune thyroiditis. Cirrhosis of liver due to hepatic enzyme dysfunction is also seen in Turner's subjects, but may be attributed to estrogen deficiency. These conditions should be ruled out in Turner's females with poor weight gain [44]. Short stature is the commonly recognized clinical feature in TS. It has intrauterine, childhood and pubertal components. Final height of these individuals is 20 cm less than average females in the corresponding ethnic group. Parental height also modifies the final height in Turner's females. Height should be plotted on Turner-specific growth chart. Growth hormone (GH) therapy with or without anabolic steroids should be instituted in all TS females whose height is below 5th percentile of the normal female growth curve. The final height of 150 cm is the achievable target in most of the TS patients. GH therapy may be started as early as 2-3 years of age, under supervision of pediatric endocrinologist and the advantages and disadvantages of the therapy should be discussed with parents and older girls with intellect to comprehend. Earlier initiation with high doses of GH accelerates growth in most Turner's girls with height increment ranges from 5-15 cm. The usual recommended starting dose of GH is 0.05 mg/kg/day (0.15 IU/kg/day). Individualization of dosing should be considered if there is poor response. GH alone should be considered for girls below 12 years. Recurrence or exacerbation of lymphedema, enlargement of naevi and elevated levels of Immunoglobulin F-I are usual side effects of prolonged usage of GH. In older girls addition of low dose of non-aromatizable steroid, such as oxandrolone should be given in addition to GH. The recommended dose is 0.05 mg/kg/day. This is preferred because of non-conversion into estrogen which

accelerates epiphyseal fusion leading to growth cessation. Girls on anabolic steroid should be monitored for virilization, glucose intolerance and clitoral enlargement. Orthopedic leg lengthening, an alternate approach to correct short stature in TS has its own limitations due its conflicting reports [51, 52].

About 90% of Turner's girls have gonadal failure, but spontaneous puberty was observed in 30% of the patients. Also in 2-5% of the patients, spontaneous menses were seen and they have the potential to conceive without medical intervention. But majority of the patients will however require pubertal induction with maintenance estrogen therapy in the later life. Estrogen induces the breast development, pelvic and uterine growth, bone mineralization and psychosocial and emotional development of the individuals. The estrogen therapy should be initiated either alone or in co-ordination with GH therapy. Since estrogen accelerates the fusion of bone epiphysis, the timing of its commencement is to achieve maximum growth without delaying the pubertal onset. Before initiation of therapy serum gonadotrophin levels for elevated FSH and sonographic examination of the status of gonads should be carried out. The optimal age to initiate estrogen therapy is 12-13 years, but not later than 14 years. Hormonal induction of puberty should resemble the normal growth and development of secondary sexual characters. Low dose natural estrogen - estradiol valerate is the drug of choice for pubertal initiation; to begin with one sixth to one quarter of adult dose, equivalent to 0.5-1mg on alternate days, increased gradually at 3-6 month intervals according to response, to complete feminization over a period of 2-3 years. Medroxyprogesterone acetate, a progestin should also be given with a dose of 5 mg/day for 12-14 days on each cycle when vaginal bleeding occurs or after 2 years of estrogen therapy to establish monthly cycles. Transdermal estrogen patches are also successfully tried, but with little success. Regular counselling for sexually transmitted diseases is to be given to all TS females and for those with spontaneous puberty has to receive contraceptive and genetic counselling [53-55].

Adult management

The primary aim of adult management is to decrease the mortality and morbidity and to increase the quality of life in Turner's women with proper medical intervention/prophylaxis. There should be a smooth transition from childhood to adult management, which starts usually at 18 years of age and the transition should continue for a period of 2-3 years starting from late pubertal period. A multidisciplinary team around a tertiary care centre should supervise the whole process [34].

Approximately about 10% of Turner's cases were first diagnosed only during adulthood. All Turner's adult females should undergo a comprehensive medical evaluation for CHD, hearing- loss, skeletal, dental problems and ophthalmological

abnormalities. Annual clinical evaluation including blood pressure, cardiac auscultation, thyroid size and function, breast examination and Pap smear has to be recorded [44]. About 15% of adults with TS suffer from significant hearing loss, which may be conductive and/or sensorineural. The hearing loss is progressive, aggravated after 35 years of age. There will be early aging with presbycusis of the affected individuals. Hearing aids are frequently advised. Frequent follow up at 3-5 years interval should be advised for all Turner's adults, especially in the presence of low risk karyotype 45X, 46X, 1 (Xq) [56].

Autoimmune thyroiditis was frequently seen in adults with TS. Fifty percent of adults showed positive antibodies and 25% of them are hypothyroid. Thyroid antibodies should be measured once in every 5 years and TSH should be estimated yearly [47]. Obesity is the common problem due to low physical activity. Life style modifications with controlled diet and exercise could prevent diabetes, hypertension and osteoporosis. It is advisable to keep waist/hip ratio less than 0.80 and body mass index (BMI) less than 25 kg/m². Complete blood analysis include hemoglobin, urea, creatinine, FBS, lipid profile, TSH, T3 and T4 and liver enzymes should be analyzed in every 2 year intervals. Liver enzymes are commonly increased in Turner's women indicating a chronic liver disease. Treatment with 17 β -estradiol improves the liver function. Inflammatory bowel disease and Crohn's disease should be excluded if there are any recurrent GIT symptoms. Women with renal collecting system anomalies should exclude for recurrent urinary tract infections [57-59]. Risk of fractures increases beyond the age of 45 years in all Turner's women. Bone mineral density should be performed in every 3-5 years. Osteoporosis may be corrected with dietary calcium supplements of 1.2 g/day, weight bearing exercises and estrogen supplements. Breast development assessment can be carried out with self-examination and mammography [60].

Majority of premature deaths in Turner's women were due to cardiovascular complications. Hypertension should be treated vigorously, because it contributes to the development of aortic root dissection. In cases of aortic root dilatations, careful monitoring by echocardiograms, MR angiography and computed tomography under cardiologist supervision are advised during spontaneous or assisted delivery. Dyslipidemia should be corrected with lipid lowering agents. The risk of atherosclerosis can be brought down by estrogen supplements. The risk of keloid formation should be kept in mind by the surgeon during any surgical procedures with appropriate precautions [59,61]. Cyclical estrogen and progesterone therapy should be given to all Turner's women to prevent signs and symptoms of estrogen deficiency. The type of the drug and dose should vary among individuals and it depends on symptoms, physical findings and bone mineral densities. The

recommended dose of oestrogen is 2 mg of 17 β -estradiol/day. The estrogen and progesterone therapy should be given in a continuous regimen rather than interrupted, together with cycles of progesterone to ensure adequate endometrial shedding. The usage of oral contraceptives should be avoided due to associated bone loss. If there is abnormal uterine bleeding, pelvic ultrasonography and endometrial biopsy should be advised. Androgen supplements may be given in some of these patients. Educational counselling on sexuality and sexually transmitted diseases also is a part of the management schedule [34,62].

Spontaneous pregnancy occurs only in few Turner's patients, but majority of them are infertile. Various assisted reproductive techniques are available to achieve pregnancy. It is essential to have a comprehensive medical, cardiac and gynaecological assessment of the potential mothers prior to pregnancy. In women with functional ovaries, the possible risk of miscarriage, major chromosomal and phenotypic abnormalities in the offspring should be considered and the pregnancy should not be delayed due to the risk of premature ovarian failure. Oocyte or embryo donation with careful planning is used to achieve pregnancy in patients without functional ovaries. Adequate preparation of the endometrium with estrogen and progesterone for 3-4 months before embryo transfer is necessary for implantation. Contracted and narrow pelvis necessitates elective caesarean section. The possibility of using cryopreserved ovarian tissue and immature oocytes obtained before ovarian regression is under investigation [34, 44].

Psychosexual and intellectual development

Turner's patients are predominantly phenotypic females with unambiguous female gender presentation. Most of them have heterosexual romantic affinities, but initiation and dating may be delayed and infrequent. This may be due to genetic/hormonal factors or due to physical discomfort in the form of short stature and infertility [63]. Most of them have limited emotional arousal, high tolerance to adversity, unassertive and over compliance. The short stature, delayed sexual development and primary amenorrhea are the key factors influencing the psychosocial development of the women rather than sex chromosomal anomaly. Young girls have adjustment problems, inability to concentrate with some are over conscious. Anxiety appears to be the major problem among the school going girls [64]. Most of them are mentally retarded and the mental retardation increases in patients with ring X chromosomes. Neuropsychological deficits include visual-spatial organization deficits, defects in social cognition, difficulty in non-verbal problem-solving and psychomotor deficits. These neuropsychological deficits may be improved with estrogen therapy [65].

In short, all Turner's patients have increased psychological risks, in the form of social, educational and behavioral components. These factors enormously affect the quality of life of these individuals. The medical and psychological interventional plan should be addressed to reinforce and support the patient's self-esteem, and to ensure that the individuals with TS should remain in mainstream of social, educational and employment activities. More importance should be given to the career and vocational planning and transformation to lead an independent life. Patients and parents are well informed about permanent learning problems even though of mild degree. Learning disabilities may be a major impediment to emancipation from family and to career enhancement, although most of them do achieve high professional status.

CONCLUSION

TS is a common chromosomal aneuploidy, characterized by short stature, primary amenorrhea with streak gonads and present in more than 60% of the cases. TS patients have different karyotypes, ranging from 45X, 45X/46XX and 45X/46XY cell sequences. The role of Y chromosomes in the development of gonadal tumours is still controversial. But the identification of Y chromosome mosaicism is clinically important, because of its association with dysgenetic gonads. This dysgenetic gonad later on develops into gonadoblastoma, a benign tumor, which undergo transformation into invasive dysgerminoma and other malignant germ cell tumours in over 60% of the individuals. All Turner's females should be screened for Y chromosome mosaicism by the cost effective PCR and with highly specific FISH, in addition to conventional cytogenetic karyotyping. A karyotype analysis of over 20-40 metaphase spreads with two different cell lines is to be carried out to clinch the diagnosis. Prophylactic gonadectomy should be advised in the patients with Y cell sequences. Short stature, primary amenorrhea and somatic anomalies are the primary clinical features of TS patients. A multidisciplinary care involving newborn screening, regular cardiovascular examination, GH and estrogen supplements with appropriate pubertal development had changed the scenario, with the hope of giving them a normal quality of life. Puberty should not be delayed and pregnancy is possible with proper uterine preparation and ovum donation. A comprehensive evaluation with proper education could lead to normal fruitful life.

ACKNOWLEDGEMENT

Author gratefully acknowledges Dr Narga Nair, Dr Mini Kariappa, Dr Ajith TA, Dr Sugathan KR, Smt Sindu and Smt Lissy of Amala Institute of Medical Sciences, Thrissur, Kerala for their valuable inspiration, guidance and assistance in preparing this manuscript.

REFERENCES

- [1] Turner HH. A syndrome of infantilism, congenital webbed neck, and cubitus valgus. *Endocrinology*. 1938; 23:566-74.
- [2] Lippe B. Turner Syndrome. *Endocrinol Metab Clin North Am*. 1991; 20(1):121-52.
- [3] Zin AR, Page DC, Fisher EM. Turner syndrome: The case of the missing sex chromosome. *Trends Genet*. 1993; 9: 90-3.
- [4] Hall JG, Gilchrist DM. Turner syndrome and its variants. *Pediatr Clin North Am*. 1990; 37:1421-36.
- [5] Mathur A, Stekol L, Schatz D, McLaren NK, Scott ML, Lippe B. The parental origin of the single X chromosome in Turner syndrome: Lack of correlation with parental age or clinical phenotype. *Am J Hum Genet*. 1991; 48:682-86.
- [6] Jacobs P, Dalton P, James R, Moose K, Power M, Robinson D, et al. Turner syndrome: A cytogenetic and molecular study. *Ann Hum Genet*. 1992; 61:471-83.
- [7] Oliveria RMR, Verreschi ITN, Lipay MVN, Eca LP, Guedes AD, Bianco B. Y Chromosome in Turner syndrome: review of the literature. *Sao Paulo Med J*. 2009; 127(6):373-78.
- [8] Gravholt CH, Fedder J, Naeraa RW, Muller J. Occurrence of gonadoblastoma in females with Turner syndrome and Y chromosome material: A population study. *J Clin Endocrinol Metab*. 2000; 85:3199-202.
- [9] Tsuchiya K, Reijo R, Page DC, Diestecher CM. Gonadoblastoma: Molecular definition of the susceptibility region on the Y chromosome. *Am J Hum Genet*. 1995; 57(6): 1400-07.
- [10] Saenger P. Clinical review 48. The current status of diagnosis and therapeutic intervention in Turner syndrome. *J Clin Endocrinol Metab*. 1993; 77: 297-301.
- [11] Bianco B, Lipay MV, Melaragno MI, Guedes AD, Verreschi IT. Detection of hidden Y mosaicism in Turner's syndrome: Importance in the prevention of gonadoblastoma. *J Pediatr Endocrinol Metab*. 2006; 19: 1113-17.
- [12] Davenport ML, Punyasavatsut N, Stewart PW, Gunther DF, Savendahl L, Sybert VP. Growth failure in early life: an important manifestation of Turner syndrome. *Horm Res*. 2002; 57:157-64.
- [13] Lyon AJ, Preece MA, Grant DB. Growth curve for girls with Turner syndrome. *Arch Dis Child*. 1985; 60: 932-35.
- [14] Rao E, Weiss B, Fukami M, et al. Pseudoautosomal deletions encompassing a novel homeobox gene cause growth failure in idiopathic short stature and Turner syndrome. *Nat Genet*. 1997;16(1):54-63.
- [15] Gravholt CH. Epidemiological, endocrine and metabolic features in Turner syndrome. *Arq Bras Endocrinol Metabol*. 2005; 49(1): 145-56.
- [16] Elsheikh M, Wass JA, Conway GS. Autoimmune thyroid syndrome in woman with Turner's syndrome—the association with karyotype. *Clin Endocrinol (Oxf)*. 2001; 55 (2):223-26.
- [17] Gravholt CH. Epidemiological, endocrine and metabolic features in Turner syndrome. *Eur J Endocrinol*. 2004; 151(6): 657-87.
- [18] Stratakis CA, Rennert OM. Turner syndrome: molecular and cytogenetics, dysmorphology, endocrine, and other clinical manifestations and their management. *The Endocrinologist*. 1994; 4(6):442-53.
- [19] Held KR, Kerber S, Kaminsky E, et al. Mosaicism in 45, X Turner syndrome: does survival in early pregnancy depend on the presence of two sex chromosomes? *Hum Genet*. 1992; 88(3):288-94.
- [20] Hassold T, Benham F, Leppert M. Cytogenetic and molecular analysis of sex-chromosome monosomy. *Am J Hum Genet*. 1988; 42(4):534-41.

- [21] Ferguson-Smith MA, Yates JR. Maternal age specific rates for chromosome aberrations and factors influencing them: report of a collaborative European study on 52965 amniocenteses. *Prenat Diagn.* 1984 Spring; 4 Spec No: 5-44.
- [22] Yorifuji T, Muroi J, Kawai M, Sasaki H, Momoi T, Furusho K. PCR-based detection of mosaicism in Turner syndrome patients. *Hum Genet.* 1997; 99(1):62-65.
- [23] Fisher EM, Beer-Romero P, Brown LG, et al. Homologous ribosomal protein genes on the human X and Y chromosomes: escape from X inactivation and possible implications for Turner syndrome. *Cell.* 1990; 63(6):1205-18.
- [24] Fernandez R, Mendez J, Pasaro E. Turner syndrome: a study of chromosomal mosaicism. *Hum Genet.* 1996; 98(1): 29-35.
- [25] Hanson L, Bryman I, Jason PO, Jakobsen AM, Hanson C. Fluorescence in situ hybridisation analysis and ovarian histology of women with Turner syndrome presenting Y- chromosome material: a correlation between oral epithelial cells, lymphocytes and ovarian tissue. *Hereditas.* 2002; 137(1): 1-6.
- [26] Nazarenko SA, Timoshevsky VA, Sukhanova NN. High frequency of tissue-specific mosaicism in Turner syndrome patients. *Clin Genet.* 1999; 56(1): 59-65.
- [27] Mendes JR, Strufaldi MW, Delcelo R et al. Y-chromosome identification by PCR and gonadal histopathology in Turner's syndrome without overt Y-mosaicism. *Clin Endocrinol (Oxf).* 1999; 50(1):19-26.
- [28] Lopez M, Canto P, Aguinaga M, et al. Frequency of Y chromosomal material in Mexican patients with Ullrich-Turner syndrome. *Am J Med Genet.* 1998; 76(2):120-24.
- [29] Chu C. Y-chromosome mosaicism in girls with Turner's syndrome. *Clin Endocrinol (Oxf).* 1999; 50(1):17-18.
- [30] Lipay MV, Bianco B, Verreschi IT. Disgenesias gonadais aspectos geneticos e clinicos [Gonadal dysgenesis and tumors: genetic and clinical features]. *Arq Bras Endocrinol Metabol.* 2005; 49(1): 60-70.
- [31] Looijenga LH, Stoop H, de Leeuw HP, et al. POU5F1 (OCT3/4) identifies cells with pluripotent potential in human germ cell tumors. *Cancer Res.* 2003; 63(9):2244-50.
- [32] Page DC. Hypothesis: a Y-chromosomal gene causes gonadoblastoma in dysgenetic gonads. *Development.* 1987; 101 Suppl:151-5.
- [33] Rosen GF, Kaplan B, Lobo RA. Menstrual function and hirsutism in patients with gonadal dysgenesis. *Obstet Gynecol.* 1988; 71(5): 677-80.
- [34] Saenger P, Wikland KA, Conway GS, Devenport M, Gravholt CH, Hintz R, et al. Recommendations for the Diagnosis and Management of Turner Syndrome. *J Clin Endocrinol Metab.* 2001; 86(7): 3061-69.
- [35] Kota SK, Gayatri K, Pani JP, Kota SK, Meher LK, Modi KD. Dysgerminoma in a female with Turner syndrome and Y chromosome material: A case-based review of literature. *Indian J Endocr Metab.* 2012; 16(3): 436-40.
- [36] Paliwal P, Sharma A, Birla S, Kriplani A, Khadgawat R. Identification of novel SRY mutations and SF1 (NR5A1) changes in patients with pure gonadal dysgenesis and 46 XY karyotype. *Mol Hum Reprod.* 2011; 17(6): 372-78.
- [37] Golbus MS. Prenatal diagnosis and fetal loss. In: Rosenfeld RG, Grumbach MM. eds. Turners syndrome. New York, Marcell Dekker. 1990: 101-08.
- [38] Ruiz C, Lamm F, Hart PS. Turner syndrome and multiple-marker screening. *Clin Chem.* 1999; 45:2259-61.
- [39] Gravholt CH, Juul S, Naeraa RW, Hansen J. Prenatal and postnatal prevalence of Turner's syndrome: a registry study. *Br Med J.* 1996; 312:16-21.
- [40] Kulkarni R, Hawkins J, Bradford WP. Prenatal diagnosis of 45X/46XX mosaicism in the fetus: should the pregnancy be terminated? *Prenatal Diagnosis.* 1969; 9: 439-41.
- [41] Koeberl DD, McGillivray B, Sybert VP. Prenatal diagnosis of 45X/46XX mosaicism and 45X: implications for postnatal outcome. *Am J Hum Genet.* 1995;57:661-66.
- [42] Zinn AR, Page DC. Turner syndrome and the Y chromosome. In: Hibi I, Takano K. eds. Basic and clinical approach to Turners syndrome. Amsterdam, Elsevier. 1993:49-56.
- [43] Manuel M, Katayama PK, Jones HWJ. The age of occurrence of gonadal tumors in intersex patients with a Y chromosome. *Am J Obstet Gynecol.* 1976; 124:293-300.
- [44] George Werther. Turner Syndrome Management Guidelines- Australasian paediatric Endocrine Group - Nov 2003. www.apeg.org.
- [45] Mazzanti L, Cacciari E. Italian Study Group for Turner Syndrome. Congenital heart disease in patients with Turner syndrome. *J Pediatr.* 1998; 133:688-92.
- [46] Lacro RV, Jones KL, Benirschke K. Coarctation of the aorta in Turner syndrome: a pathologic study of fetuses with nuchal cystic hygromas, hydrops fetalis and female genitalia. *Pediatrics.* 1988; 81:445-51.
- [47] Radetti G, Mazzanti L, Paganini C, et al. Frequency, clinical and laboratory features of thyroiditis in girls with Turner's syndrome. The Italian Study Group for Turner's syndrome. *Acta Paediatr.* 1995; 84:909-12.
- [48] Barrenas M, Landin-Wilhelmsen K, Hanson C. Ear and hearing in relation to genotype and growth in Turner syndrome. *Hear Res.* 2000; 144:21-28.
- [49] Suwa S. Standards for growth and growth velocity in Turner syndrome. *Acta Paediatr Jpn.* 1992; 34:206-20.
- [50] Tanaka T, Sato M, Tanae A, Hibi I. Glucose tolerance and Turner syndrome. In: Hibi I, Takano K. eds. Basic and clinical approach to Turner syndrome. Amsterdam, Elsevier. 1993: 107 -112.
- [51] Nilsson KO, Albertsson-Wikland K, Alm J, et al. Improved final height in girls with Turner's syndrome treated with growth hormone and oxandrolone. *J Clin Endocrinol Metab.* 1996; 81: 216-21.
- [52] Ranke MB, Lindberg A, Chatelain P, et al. Prediction of long-term response to recombinant human growth hormone (GH) in Turner syndrome: development and validation of mathematical models. *J Clin Endocrinol Metab.* 2000;85:4212-18.
- [53] Hovatta O. Pregnancies in women with Turner's syndrome. *Ann Med.* 1999;31:106-10.
- [54] Naeraa RW, Nielsen J, Kastrup KW. Growth hormone and 17 β -estradiol treatment of Turner girls-2 year results. *Eur J Pediatr.* 1993; 153:72-77.
- [55] Kaneko S, Kawagoe S, Hiroi M. Turner syndrome - review of the literature with reference to a successful pregnancy outcome. *Gynecol Obstet Invest.* 1990; 29: 81-87.
- [56] Hultcrantz M, Sylven L, Borg E. Ear and hearing problems in 44 middle aged women with Turner syndrome. *Hear Res.* 1994; 76: 127-32.
- [57] Sylven L, Hagenfeldt K, Brondum NK, von Schoultz B. Middle-aged women with Turner's syndrome: medical status, hormonal treatment and social life. *Acta Endocrinol (Copenh).* 1991; 125: 359-65.
- [58] Gravholt CH, Naeraa RW, Fisker S, Christiansen JS. Body composition and physical fitness are major determinants of the growth hormone-IGF axis aberrations in adult Turner syndrome with important modulations by treatment with 17 β -estradiol. *J Clin Endocrinol Metab.* 1997; 82: 2570-77.

- [59] Gravholt CH, Naeraa RW, Nyholm B, et al. Glucose metabolism, lipid metabolism, and cardiovascular risk factors in adult Turner syndrome: the impact of sex hormone replacement. *Diabetes Care*. 1998; 21:1062-70.
- [60] Landin-Wilhelmsen K, Bryman I, Windh M, Wilhelmsen L. Osteoporosis and fractures in Turner syndrome-importance of growth promoting and oestrogen therapy. *Clin Endocrinol (Oxf)*. 1999; 51:497-592.
- [61] Birdsall M, Kennedy S. The risk of aortic dissection in women with Turner syndrome. *Hum Reprod*. 1996; 11:1587.
- [62] Gravholt CH, Svenstrup B, Bennett P, Christiansen JS. Low androgen levels in adult Turner syndrome: influence of female sex hormones and growth hormone status. *Clin Endocrinol (Oxf)*. 1999; 50: 791-800.
- [63] McCauley E, Sybert VP, Ehrhart AA. Psychosocial adjustment of adult women with Turner syndrome. *Clin Genet*. 1986; 29: 284-90.
- [64] McCauley E, Kay T, Ito J, Treder R. The Turner's syndrome: cognitive deficits, affective discrimination and behavioral problems. *Child Dev*. 1987; 5: 464-73.
- [65] Rovet J. The cognitive and neuropsychological characteristics of females with Turner syndrome. In: Berch DB, Bender BG, eds. Sex chromosome abnormalities and behaviour: psychological studies. Boulder, Westview Press for the American Association for the Advancement of Science. 1990: 1-77.

AUTHOR(S):

1. Dr. S Iqbal

PARTICULARS OF CONTRIBUTORS:

1. Professor, Department of Anatomy, Amala Institute of Medical Sciences, Amala Nagar, Thrissur, Kerala-680555, India.

NAME, ADDRESS, E-MAIL ID OF THE CORRESPONDING AUTHOR:

Dr. S Iqbal,
Professor, Department of Anatomy, Amala Institute of Medical Sciences, Amala Nagar, Thrissur, Kerala, India.
Phone: 9447085253, E-mail: dr.iqbal.s@gmail.com

FINANCIAL OR OTHER COMPETING INTERESTS:

None.

Date of Publishing: Jun 15, 2014